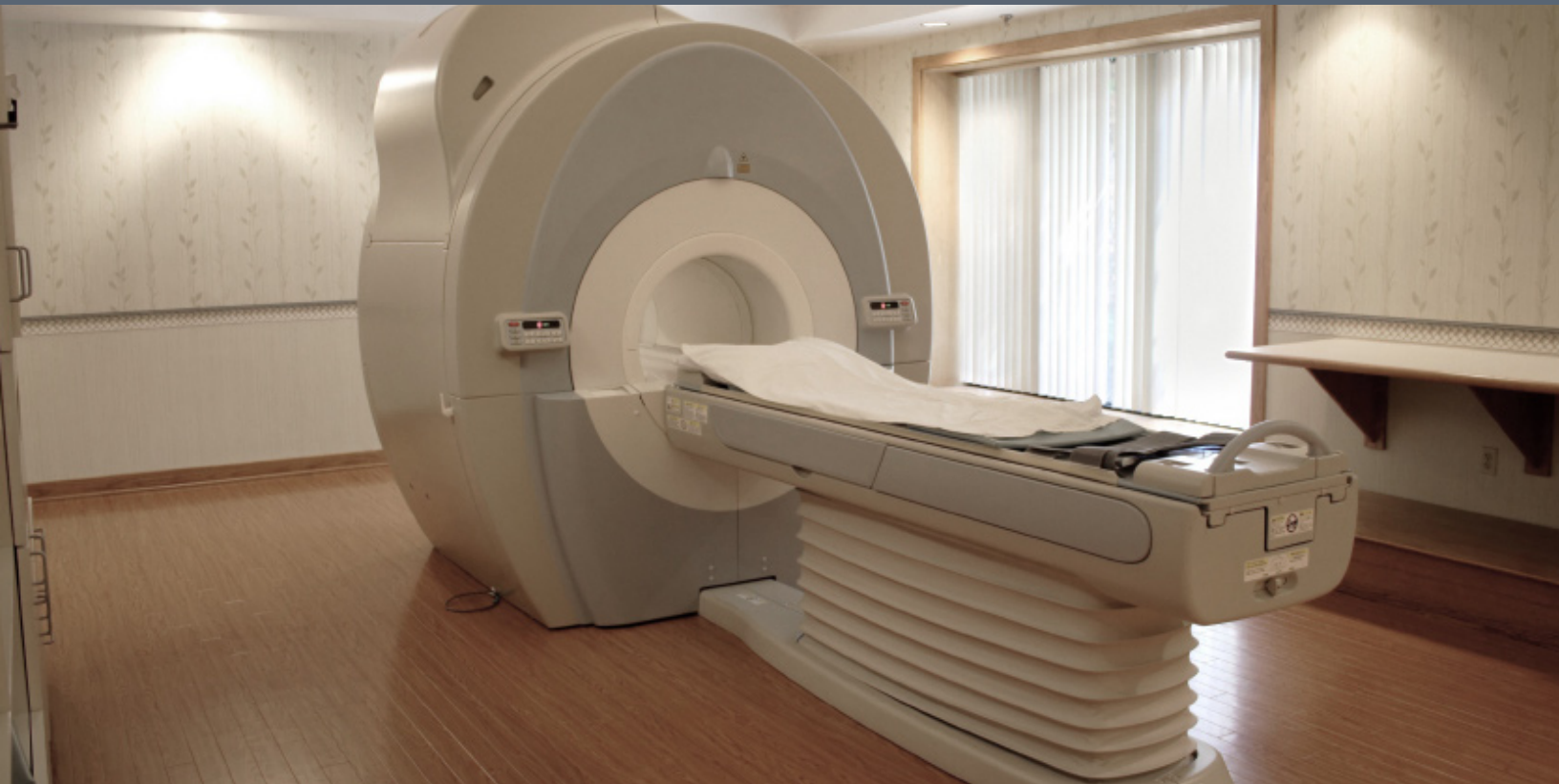



# GADOLINIUM SYSTEMIC FIBROSIS

ORGANIZED BY THE LAWYERS AT ANAPOL SCHWARTZ. © 2009 ALL RIGHTS RESERVED.

CONTACT LAWYER: BARRY HILL, ESQUIRE  
CALL: (215) 735-0364  
EMAIL: [BHILL@ANAPOLSCHWARTZ.COM](mailto:BHILL@ANAPOLSCHWARTZ.COM)  
READ MORE INFORMATION ONLINE AT: [www.anapolschwartz.com](http://www.anapolschwartz.com)

DISCLAIMER: This information is not intended to replace the advice of a doctor. Please use this information to help in your conversation with your doctor. This is general background information and should not be followed as medical advice. Please consult your doctor regarding all medical questions and for all medical treatment.





## CONTRAST SOLUTIONS BASICS

### CT and MRI distinguished

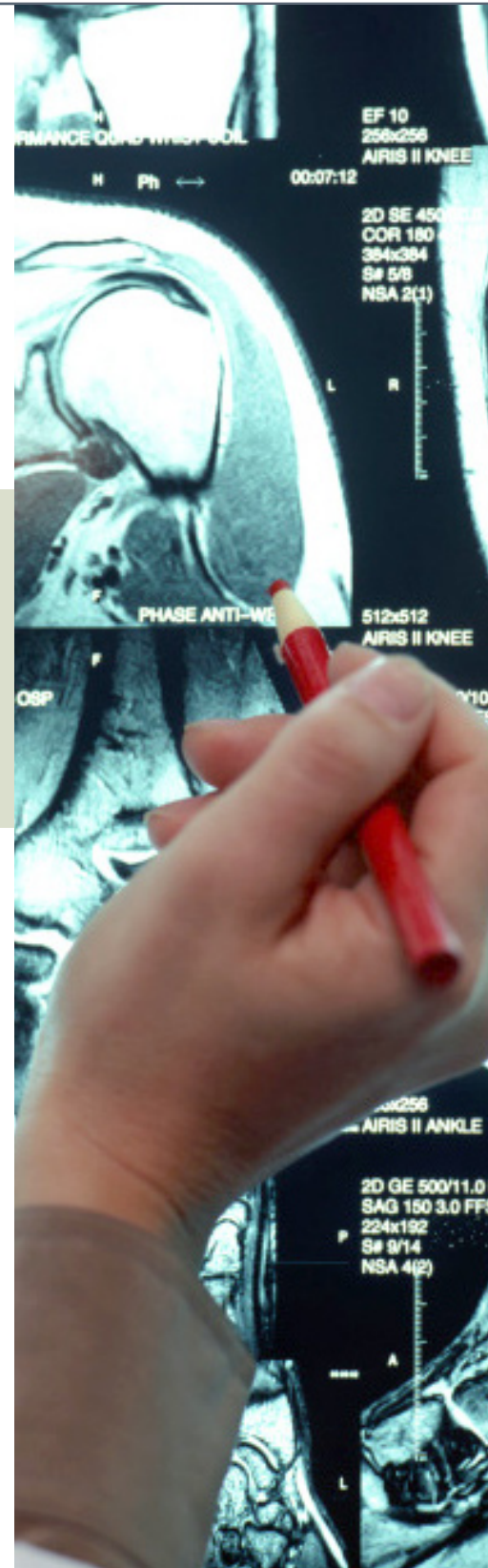
- CT uses a combination of x-rays and computer technology.
- MRI uses a combination of a strong magnetic field, radiofrequency, and computer technology.

### Radiographic Contrast Material

- Can be called contrast material, agent, medium, or solution.
- An internally-administered substance that has a different opacity from soft tissue on radiography, MRI, or CT.
- Contrast is used to better visualize areas where blood flow exists.

### Distinction between MRI contrast and CT contrast

- MRI contrast is a gadolinium-based solution which will show blood vessels and blood flow.
- CT contrast is an iodine-based solution that will show areas of blood vessels and blood flow.
- Probably not a good case if person had only CT.
- Enhancement solutions used from CT ordinarily do not contain gadolinium.
- May be rare exceptions – if person has NSF, keep looking



## REASONS FOR USING CONTRAST WITH MRI

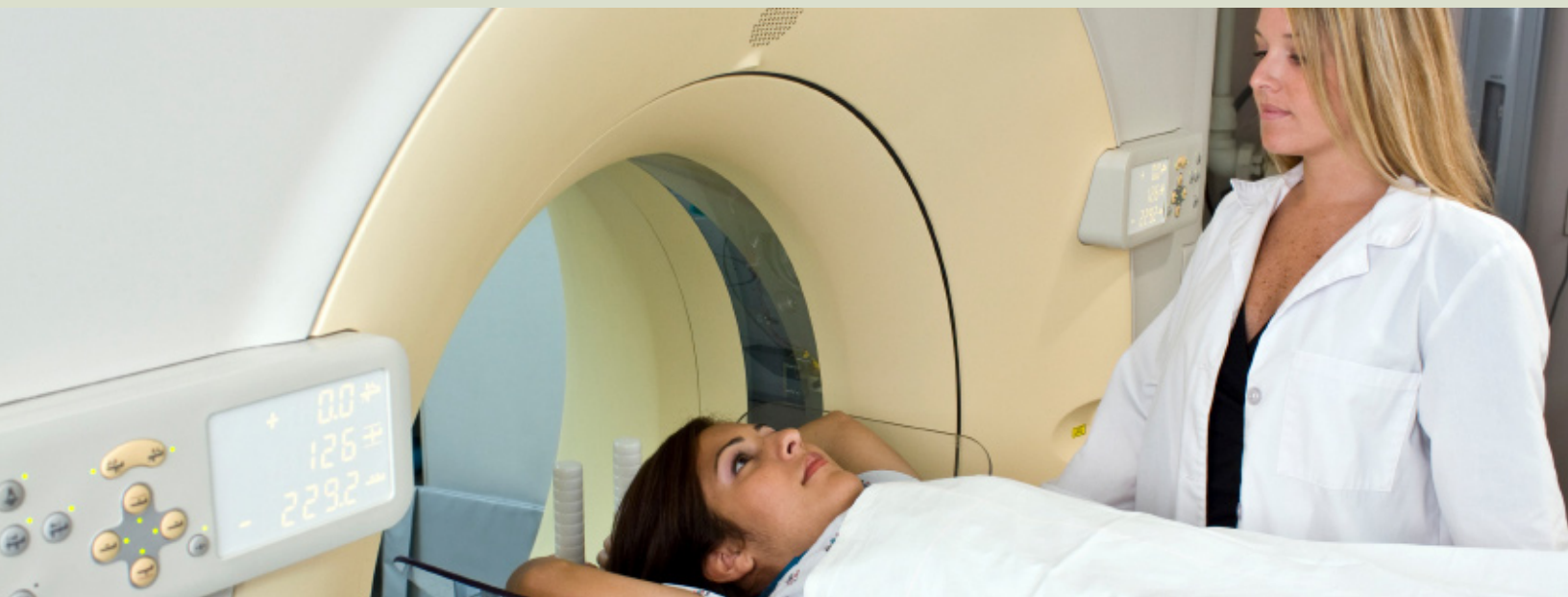- Increased distinction between normal and pathologic tissues
- Some things that are not clear on unenhanced images become obvious with contrast.
- Increased MRI sensitivity.
- Sometimes better able to identify lesion in question.
- Can show physiologic and functional information in addition to lesion delineation.
- Imaging of arteries and veins with contrast enhanced angiography (CE MRA).

## NON-CONTRAST MR ANGIOGRAPHY

### From Toshiba Medical Systems:

“Based on a growing body of evidence that links gadolinium-based contrast agents with Nephrogenic Systemic Fibrosis/Nephrogenic Fibrosing Dermopathy (NSF/NFD), there is a clear need for rapid, ultra-clear MRA without the use of contrast agents.”

“In 1998, Toshiba pioneered non-contrast MR imaging. Now, with over 8 years of clinical experience, Toshiba’s Vantage systems are the only systems available with a complete suite of contrast-free MRA techniques.”



## FDA ALERT

(6/2006, updated 12/2006 and 5/23/2007)

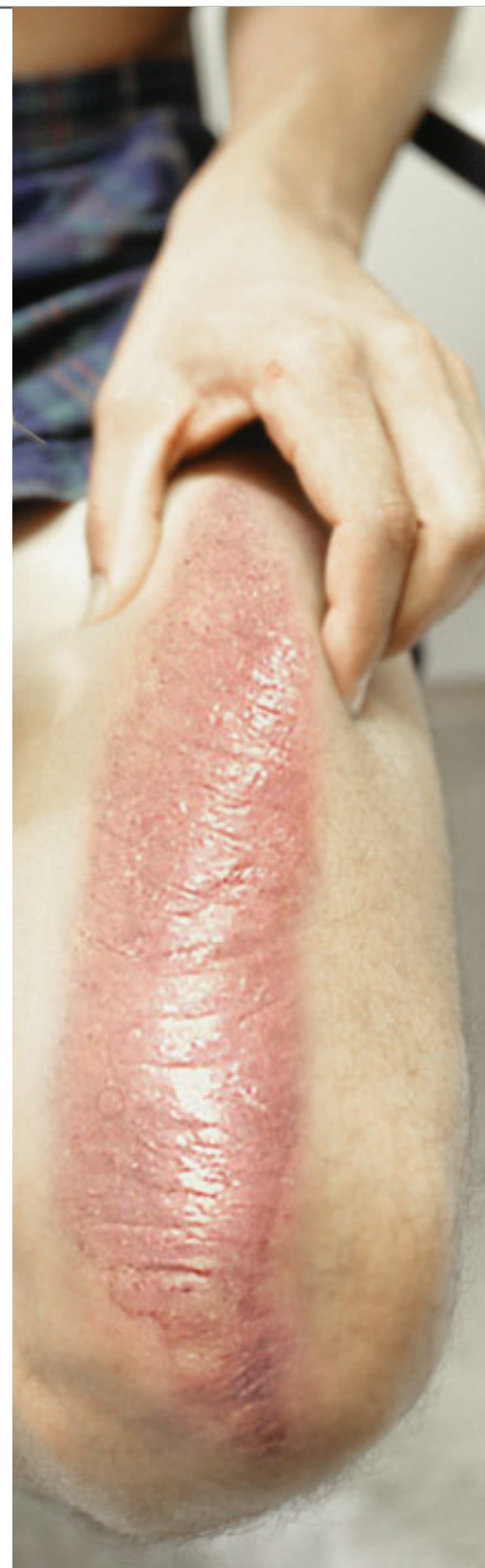### **Information for Healthcare Professionals Gadolinium-Based Contrast Agents for Magnetic Resonance Imaging**

#### ***Boxed Warning:***

- Exposure increases the risk for NSF in patients with:
  - acute or chronic severe renal insufficiency
  - acute renal insufficiency of *any* severity due to the hepatorenal syndrome or in the perioperative liver transplantation period.
- NSF is a debilitating and sometimes fatal disease affecting the skin, muscle, and internal organs.
- Avoid use unless the diagnostic information is essential and not available without contrast.
- Screen all patients for renal dysfunction.
- do not exceed recommended dose in product labeling.
- Allow time for elimination before readministration.

### **Nephrogenic Systemic Fibrosis**

- First described in 1997 in patients with end stage renal disease
- Characterized by scleroderma-like skin changes that mainly affect the limbs and trunk.
- Can progress to cause flexion contracture of joints.
- Fibrotic changes may also affect other organs such as muscles, heart, liver and lungs.
- The disease can be aggressive in some patients leading to serious physical disability or death.
- Old terminology: Nephrogenic Fibrosing Dermopathy (NFD).
- Suggested new terminology: Gadolinium Fibrosing Dermopathy.



## FIRST PUBLISHED REPORT

Scleromyxoedema-like cutaneous disease in renal dialysis patients.

Cowper et al.  
The Lancet  
16 September 2000

Nephrogenic Fibrosing Dermopathy/Nephrogenic Systemic Fibrosis:  
Report of a New Case with Literature Review

Daram SR. Amer J Kidn Dis. (Oct. 2005) 46;4:754-759

**People with NSF don't know what the future holds,  
because doctors don't know enough to tell them.**

## Nephrogenic Systemic Fibrosis

- No consistently effective treatment.
- Photophoresis might help but cost \$8,000 per treatment every two weeks.
- Disease too new for physicians to know how to treat it or to give a prognosis.
- Some treatment like high-dose steroids can have fatal consequences.

## Time from gadolinium solution administration to NSF symptoms:

Two days to six years reported in literature.

### RESEARCH LETTERS

We thank Karen Brown, Moira Bruce, Cahan McKeown, David Pemberton, Diane Ritchie, and the Scottish Blood Transfusion Service. The project is funded by the Department of Health.

- 1 Bruce ME, Will RG, Ironside JW, et al. Transmission to mice infects the 'new variant' CJD is caused by the BSE agent. *Nature* 1997; 389: 488-501.
- 2 Schmeier MJ, Jenny A, Curlip RC. Use of capillary sodium dodecyl sulfate gel electrophoresis to detect the prion protein extracted from scrapie-infected sheep. *J Chromatogr B Biomed Appl* 1997; 697: 223-29.
- 3 Fraser JD, Bruce M, McConnell I, Cline A, Fraser H. Detection of BSE infectivity in brain and spleen of experimentally infected sheep. *Vet Rec* 1996; 138: 546-48.
- 4 Hill AF, Zeidler M, Ironside J, Collinge J. Diagnosis of new variant Creutzfeldt-Jakob disease by tissue biopsy. *Lancet* 1997; 349: 99-100.
- 5 Goldman W, Hunter N, Smith G, Fraser J, Hope J. PrP genotypes and agent effects in scrapie: change in elastic interaction with different strains of agent in sheep, a natural host of scrapie. *J Gen Virol* 1994; 75: 919-25.

Institute for Animal Health, Compton, Newbury, UK (F Houston mc, CJ Bestock mc); and Institute for Animal Health, Neuropathogenesis Unit, Edinburgh, EH9 3JF, UK (N Hunter mc, JD Postar mc, Angela Chong mc)

Correspondence to: Dr N Hunter

## Scleromyxoedema-like cutaneous diseases in renal-dialysis patients

Shawn E Cowper, Howard S Robin, Steven M Steinberg, Lyndon D Su, Samardeep Gupta, Philip E LeBoit

15 renal dialysis patients have been identified with a skin condition characterized by thickening and hardening of the skin of the extremities and an increase in dermal fibroblast-like cells associated with collagen remodelling and mucin deposition. The disease closely resembles scleromyxoedema, yet has significant enough clinical and histopathological differences to warrant its designation as a new clinicopathological entity.

Since March, 1997, we have identified 15 renal-dialysis patients in California, Michigan, Ohio, and Mississippi,

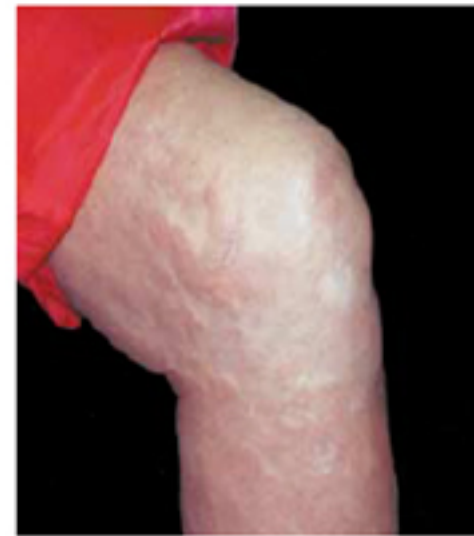

Figure 1: A 31-year-old woman with a haemodialysis-associated cutaneous fibrosing disorder.



## EPIDEMIOLOGY

- Affects both sexes equally
- Age range reported from 8 to 87 years
- Occurs worldwide in all races

**Causation:**  
The cause of NSF remains unknown.

All of our patients with NSF had been exposed to gadodiamide before their first sign of NSF. The median time from exposure to first medically recorded note of NSF was 25 days. In some cases, the delay was short and the link between exposure and NSF seemed obvious. However, in others, NSF developed less dramatically, had a more insidious course, and was diagnosed later. Importantly, we have not observed a single case of NSF among patients who were not exposed to gadodiamide. Consequently, the odds ratio for acquiring NSF when exposed is high and statistically highly significant in our material.



## GADOLINIUM

- Gadolinium is a metal.
- It is an element listed in periodic table of elements.
- Found in the earth's surface.
- Not in human body naturally,
- No sane or legal means of exposure other than through injection of a gadolinium-based contrast solution.
- Poisonous.

## When was this known?

“It seems reasonable, however, to suggest caution in the use of any of these agents in patients with seriously impaired renal function in which circumstances the material is retained for a prolonged period.”

Dawson P, Gadolinium Chelate MR Contrast Agents (Editorial) Clin Radiol (1994) 49:439-442.

## Gadolinium Metal

**chemical element: Gd ( granular )**

Ultra pure quantities of the element Gadolinium (atomic number 64), ideal for element collectors of those conducting experiments/producing alloys with pure Gadolinium metal. It has the highest thermal neutron capture cross-section of any known element. Gadolinium becomes superconductive below a critical temperature of 1.083 K. It is strongly magnetic at room temperature, and exhibits ferromagnetic properties below room temperature. Gadolinium metal is used as an emergency shut-down measure in some types of nuclear reactors.

**5 grams: \$10.00    10 grams: \$20.00**

**Potentially hazardous chemicals require an adult signature upon delivery.**



Because gadolinium is poisonous, contrast solution manufacturers use chelate chemicals to prevent free gadolinium in the body.

- Chelates work like insulation.
- Transmetalation (insulation lost) occurs over time.
- f clearance from body takes longer than normal, transmetalation can result in free gadolinium.
- Normal clearance time is under two hours.
- Renally impaired person can take 30 hours or more

## CASE SELECTION CRITERIA

### NSF Diagnosis

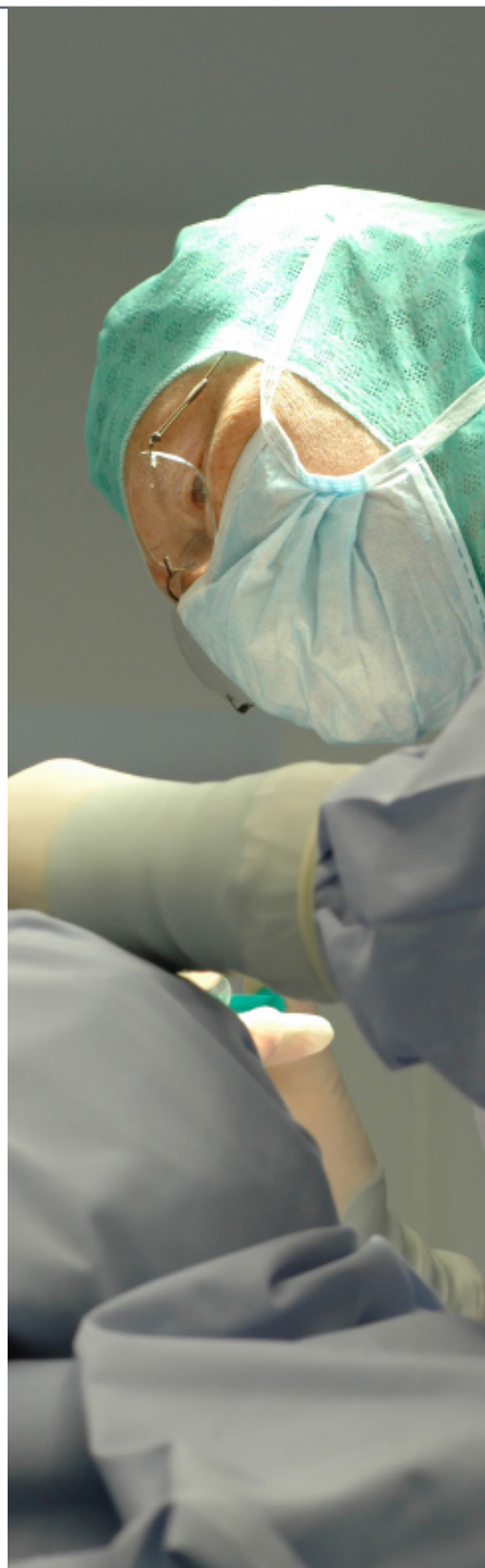
- Definitive diagnosis made by skin biopsy at an involved site.
- Usually punch biopsy, but sometimes more involved wedge biopsy.
- Diagnosis made clinically in some diabetics because of diabetic risks of skin biopsy.

### Punch biopsy tools

These come in a variety of sizes. Family practice physicians use them routinely, but some do not go deeper than 5 mm and refer to dermatologist for deeper penetration.

## WHAT CASES TO TAKE?

- If NSF is confirmed by biopsy, take the case.
- If diagnosis made clinically in diabetic probably take the case.
- If NSF is not confirmed by biopsy or diagnosis made clinically, do not take the case, until and unless diagnosis made.
- Traditional approach of getting medical records and having an expert review them will not work.
- Clients need to be told up front that there is no provable case without NSF diagnosis.





## Yale Dermatopathology Laboratory

P.O. Box 208059  
15 York Street, New Haven, Connecticut 06520-8059  
Telephone: 203.785.4094 Fax: 203.785.6869



### Consultation Report

Pathology #: <b>D04-053584</b>	Patient: <b>White, Anna</b>	DOB: <b>5/10/1970</b>
Service: <b>11/30/2004</b>	Address: <b>1209 Byron Rd</b>	Age: <b>34</b>
Received: <b>11/30/2004</b>	<b>CHARLESTON, SC 29407</b>	Gender: <b>F</b>
Reported: <b>12/2/2004</b>	Physician: <b>John C Maize, M.D. (877) 272-7284</b>	

**DIAGNOSIS: LEG, RIGHT**  
**CONSISTENT WITH NEPHROGENIC FIBROSING DERMOPATHY**  
**AND CONCURRENT SPONGIOTIC DERMATITIS**

Note: Thank you for the opportunity to review this case. I concur with the histologic interpretation. I have seen one other case of NFD in which spongiotic dermatitis was concurrent with the NFD. Please let the patient know that Yale University maintains a registry of NFD cases (<http://www.icnfd.org>) and would be very interested in interviewing her by telephone. If this is acceptable, please have her, or Dr. Benbenisty contact us.

**CLINICAL IMPRESSION:**  
 34 YO WF with ESRD – On peritoneal dialysis x 4 mos. ?NFD.

**GROSS DESCRIPTION:**  
 Received are four slides labeled SCD-04-16321 (A-1, A-2, A Colloidal Iron, A Colloidal Iron Control) from Dermath Diagnostics, Mt. Pleasant, SC.

**MICROSCOPIC DESCRIPTION:**  
 Sections consist of a punch biopsy of skin demonstrating epidermal spongiosis. In the dermis there is a mainly superficial perivascular lymphohistiocytic inflammatory infiltrate with eosinophils. The dermis demonstrates diffusely increased numbers of spindle cells associated with increased dermal mucin well-demonstrated by a colloidal iron stain.

Final Diagnosis performed by  
 Sharon Cowper M.D.  
 Electronically signed 12/2/2004 2:42PM



## MANUFACTURERS

### **Five gadolinium contrast solutions are approved for sale in the US:**

1. Omniscan (GE)
2. Magnevist (Bayer)
3. OptiMARK (Mallinckrodt/Tyco)
4. MultiHance (Bracco)
5. ProHance (Bracco)

### **FDA May 23, 2007**

Reports of NSF following administration of gadolinium solutions show the risk of NSF by brand of solution used is:

1. Omniscan by GE (highest risk)
2. Magnevist by Bayer (second highest risk)\*
3. OptiMARK by Tyco (third highest risk)

There are no reported cases of NSF with ProHance or MultiHance alone (both by Bracco)

\*Bayer rank above Tyco might be attributable to higher sales for Bayer's Magnevist than Tyco's OptiMARK, and actual risk for Bayer product might be significantly lower than Tyco or GE.

## CURRENT LITIGATION

### Gadolinium MDL

In re: Gadolinium Based Contrast Agents Product Liability Litigation. Case No. 1:08 GD 50000, MDL 1909, United States District Court, Northern District of Ohio at Cleveland

- MDL 1909
- Cleveland
- Judge Polster
- First meeting March 5, 2008
- Second meeting April 8, 2008

## STATE COURTS

- **New Jersey**
- Pennsylvania
- California
- Illinois
- **Missouri**

Others with diversity-destroying defendant.

